

# Stage IIIA non-small cell lung cancer: a contraindication for video-assisted thoracic surgery lobectomy? – a narrative review

Philipp Schnorr<sup>1</sup>, Donatas Zalepugas<sup>1,2</sup>, Davide Patrini<sup>3</sup>, Joachim Schmidt<sup>1,2</sup>, Benedetta Bedetti<sup>1</sup>

<sup>1</sup>Department of Thoracic Surgery, Malteser Hospital, Bonn, Germany; <sup>2</sup>Department of General-, Visceral-, Thoracic and Vascular Surgery, University Hospital Bonn, Bonn, Germany; <sup>3</sup>Department of Thoracic Surgery, University College London Hospitals NHS Foundation Trust, London, UK

*Contributions:* (I) Conception and design: P Schnorr, B Bedetti; (II) Administrative support: D Patrini; (III) Provision of study materials or patients: D Zalepugas, J Schmidt; (IV) Collection and assembly of data: P Schnorr; (V) Data analysis and interpretation: B Bedetti, J Schmidt; (VI) Manuscript writing: All authors; (VII) Final approval of manuscript: All authors.

*Correspondence to:* Philipp Schnorr, MD, Malteser Hospital Bonn, Von-Hompesch-Str. 1, 53123 Bonn, Germany.

Email: philipp.schnorr@malteser.org.

**Abstract:** Answering the question about contraindications for video-assisted thoracic surgery (VATS) in stage IIIA non-small cell lung cancer (NSCLC) is not simple, as stage IIIA relates to a heterogeneous group of bronchogenic carcinomas with locoregional involvement by extension of the primary tumor as well as ipsilateral nodal involvement posing a significant challenge in terms of surgical indication. VATS is imposing over open surgery as the standard of surgical care for early stage lung cancer, showing benefits in postoperative pain, recovery, morbidity and preservation of lung function while being equivalent in terms of oncologic outcome. To date the role of minimally invasive surgery in stage IIIA lung cancer has been reviewed only in few aspects: the practice of VATS in stage IIIA lung cancer has to be considered carefully in relation to the patient's clinical background taking also into account the surgical experience of the operating surgeons. Up to date, the choice of VATS in stage IIIA lung cancer seems to be feasible in selected cases with at least equivalent outcomes in comparison to open surgery. With the progression of the learning curve of the VATS technique as well as the development of dedicated instrumentation it is plausible that a larger number of cases of stage IIIA lung cancer will be treated through VATS in the near future. The aim of this review article is to describe feasibility, technical aspects and outcomes of VATS lobectomy in patients with stage IIIA NSCLC.

**Keywords:** Locally advanced lung cancer; video-assisted thoracic surgery (VATS); minimally invasive chest wall surgery; lung cancer surgery after induction therapy; N2 nodal involvement

Received: 05 June 2020; Accepted: 23 October 2020.

doi: 10.21037/ccts-20-115

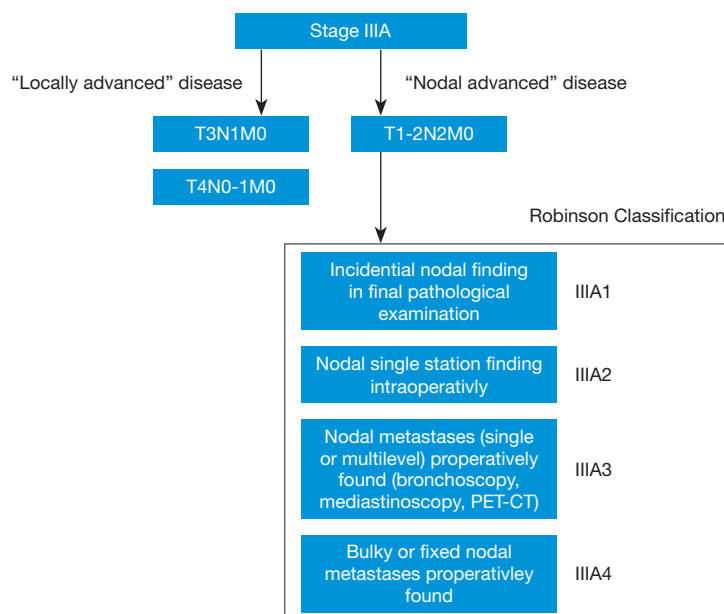
**View this article at:** <http://dx.doi.org/10.21037/ccts-20-115>

## Introduction

Stage IIIA lung cancer represents a heterogeneous group with a great variety regarding tumor size, localization and extension disease as well as nodal involvement. Therefore, the treatment strategy varies in every group of patients, depending on the above-mentioned factors. The last update of the lung cancer staging system (8<sup>th</sup> edition) from the Union for International Cancer Control in January 2017

confirms the heterogeneity of stage IIIA patients and their treatment (1).

Video-assisted thoracic surgery (VATS) is increasingly replacing open surgery as the standard of surgical care for early stage lung cancer, showing benefits in postoperative pain, recovery, morbidity and preservation of lung function while being equivalent in terms of oncologic outcome. However, in advanced stage lung cancer the use of VATS is still debated (2).



**Figure 1** Flow chart of stage IIIA lung cancer.

The objective of this review is to determine if there is evidence to rule out contraindications for VATS-lobectomy in stage IIIA. We will look into the possibilities of minimally invasive approaches for advanced lung cancer to understand their advantages or limits.

It is our opinion that there should be a clear division of nodal advanced (IIIA-N2) and locally advanced (T3-4N1, T4N0) disease (*Figure 1*).

We present the following article through a selective literature search on PubMed, Embase and Scopus and in accordance with the Narrative Review reporting checklist (available at <http://dx.doi.org/10.21037/ccts-20-115>).

### **Nodal advanced (IIIA-N2)-disease**

The subgroup of IIIA-N2-positive lung cancer can be divided according to the Robinson classification into another four subgroups (IIIA1–4) (*Figure 1*) (3). This classification refers to the timing of diagnosis of the lymph node (LN) involvement. IIIA1 is defined as the incidental diagnosis of N2-involvement in the final histopathological specimen after surgical resection and IIIA2 is recognized during surgery. Stage IIIA1 and IIIA2 are not known preoperative, so there is no contraindication for the VATS approach due to missing knowledge of the real nodal status. Question remains if VATS can achieve the same Lymph node dissection efficacy as open surgery in lung

cancer. A predictor for this is a nodal upstaging and it still remains controversial if VATS shows equal results in upstaging mediastinal LN involvement. A meta-analysis with 7,568 participants from 36 studies showed that the total number of resected mediastinal LNs was smaller through VATS than through thoracotomy (4). Possibly the greatest limitation of these findings might be that the number of dissected LNs varied significantly between the included studies. In fact, different surgeons might have different approaches for LND and they might be at dissimilar stages of their learning curve. Other large studies suggest the same findings and recommend that surgeons should be encouraged to apply a more systematic approach for LND during VATS lobectomy for lung cancer (5,6).

Robinson classification IIIA3 and 4 describe preoperatively known mediastinal nodal involvement. IIIA3 is defined as nodal involvement in single or multiple stations and IIIA4 as multilevel and extended LNs in size >2–3 cm. Besides that a further division of pN2-disease according to International Association for the Study of Lung Cancer Lung Cancer Staging Project should be considered (7): pN2-disease without pN1-involvement referred to as skip-metastasis (pN2a1), pN2 at a single station with pN1 involvement (N2a2) and pN2 at multiple stations (N2b) might be divided and treated differently as they show aberrant survival (8)

In potentially resectable cases, surgery should be part of a multidisciplinary, multimodal approach and the decision made by an interdisciplinary tumour board (9). In fact, surgery can be performed as first step in an adjuvant setting or after induction therapy. In case of neoadjuvant treatment with chemotherapy (CHT) or radio-chemotherapy (RCHT), the comparison between VATS and open surgery is the topic of many debated publications over the last years, that show that there is not a univocal therapeutic strategy for this group of patients, yet (10-19).

### **VATS-Lobectomy after induction therapy**

Most surgeons remain concerned regarding VATS as surgical treatment after neoadjuvant induction therapy due to the presence of tissue adhesions and fragile blood vessels. The Italian VATS group presented a recent publication comparing stage IIIA-N2 patients with and without neoadjuvant therapy undergoing VATS lobectomy showing no significant difference in conversion rates for bleeding or difficulties in pulmonary artery dissection (10).

Already in 2006, Petersen *et al.* published a series of 97 patients undergoing surgery after induction therapy with CHT or RCHT with 12 patients being resected over a VATS approach versus 85 with thoracotomy. The outcomes regarding the number of dissected LNs, 30-day-mortality, major complications and 2-year-survival showed no significant difference between the two groups (11). In the following years, a small number of single center retrospective observational studies were published addressing the same question by comparing VATS to thoracotomy after induction therapy. Sample sizes ranged from 17 to 69 patients undergoing VATS (12-16). Yang *et al.* in 2016 from the same working group as Petersen showed in the largest single-centre-study with 69 patients that VATS is not inferior to thoracotomy regarding the number of dissected LNs or 30-day-mortality. The VATS-group had even a significant better outcome in the 3-year-survival in both univariate and multivariate analysis (12).

In 2020 the same study group published data extracted from the National Cancer Database of patients who received neoadjuvant therapy followed by lobectomy, with 2,887 patients meeting inclusion criteria. With 676 patients being operated through VATS, this is by far the largest cohort assessing this question so far. Yang *et al.* showed that again VATS was associated with decreased length of stay while showing no significant variances in 30- and 90-day-mortality compared to open surgery. In addition

to equivalent short-term outcomes, long term there were no significant differences in the 5-year survival in both the whole cohort, as well as in a propensity score-matched analysis of 876 patients (17).

It has to be mentioned that in these publications the majority of the patients, but not all of them were in stage IIIA, so a definite answer for the specific question about contraindications for VATS in this stage cannot be given. But based on these data, there seem to be no contraindications for minimally invasive surgery after induction therapy. Another crucial topic, which will not be further discussed in this paper, is the importance of mediastinal re-staging after induction therapy, which leads to a better selection for suitable candidates that really benefit from surgical treatment (18).

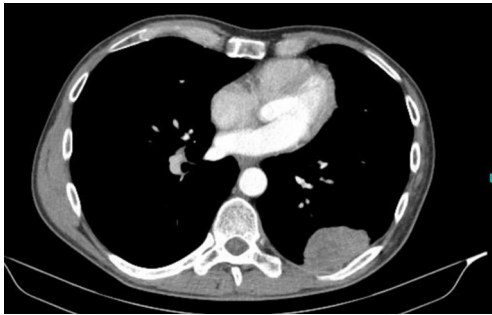
One possible look into the future might be the advancement of the even less invasive approach of uniportal resections. Ismail *et al.* described 18 patients undergoing major resections by uniportal VATS after neoadjuvant CHT with no significant difference regarding 30-day-mortality or perioperative complications compared to 136 patients without induction therapy (19).

Another group of patient that may pose significant challenges in terms of surgical management are the one requiring surgery following neoadjuvant immunotherapy. Anatomical resections seem to be even more challenging due to hilar and mediastinal fibrosis but technically feasible in small cohorts and preliminary data of ongoing clinical trials published to date, even though a high rate of conversions up to 50% is reported in the data (20-22).

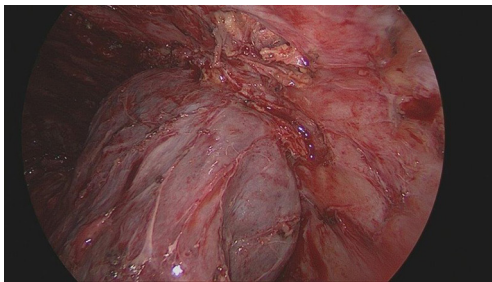
### **Locally advanced (IIIA-T3-4 N1, T4 N0) disease**

The major principle of surgical treatment of non-small cell lung cancer (NSCLC) is the complete resection of the tumor and its anatomical unit with microscopically proven clear resection margins. With locally advanced stages, especially tumours invading adjacent structures, this is a known challenge. For instance, lung sparing resections such as bilobectomies and sleeve resections for centrally located tumours and chest wall resections are challenging but practiced procedures. Major progresses have been made given also the progresses of the technology in the last years. The question remains here as well: can thoracoscopy be considered a valid if not a better alternative approach to thoracotomy?

In neoadjuvant treatment concepts, many of these patients receive induction CHT or RCHT similar to



**Figure 2** Preoperative CT-scan showing the tumour in the left lower lobe invading the chest wall.



**Figure 3** Intraoperative image showing the tumour invading the chest wall.

patients with N2-disease. Therefore, the discussion about VATS-lobectomy after induction therapy, as mentioned above, is important here as well. As discussed earlier in this publication many studies tend to mix N2-, locally-advanced and neoadjuvant-treated patients, so a differentiation between these entities remains difficult.

In the following paragraphs, we will discuss the feasibility of the VATS approach according to different T-stages including tumours infiltrating adjacent structures:

- (I) T3N1:
  - (i) Chest wall;
  - (ii) Phrenic nerve;
  - (iii) Pericardium.
- (II) T4N0-1:
  - (i) Heart;
  - (ii) Great vessels (central pulmonary artery, intrapericardial pulmonary vein, v. cava and aorta);
  - (iii) Diaphragm;
  - (iv) Oesophagus;
  - (v) Trachea/carina;
  - (vi) Vertebral body

### *T3N1-disease and the challenge of chest wall infiltration*

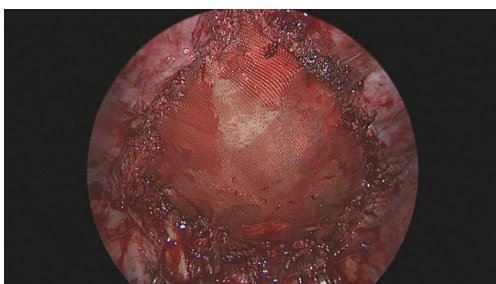
Tumours greater than 5 cm and less than 7 cm with N1-lymph node involvement, as well as tumours invading chest wall, parietal pericardium, phrenic nerve or tumours with separate nodules in the same lobe are considered stage IIIA. Most cases can be technically handled very well in VATS, but chest wall invasion remains challenging.

Approximately 5% to 8% of NSCLC patients needing a chest wall resection due to local invasion (23) and again neoadjuvant radiotherapy has been reported to be beneficial in terms of reduced local recurrence, survival rates and less extensive resection in selected patients. The first patient described undergoing VATS-lobectomy-en-bloc-chest wall resection was in 2000 by Widmann *et al.* They performed a VATS-lobectomy of the left upper lobe en-bloc with two ribs without the need of reconstruction (24). After that, only a few retrospective case series were published. Most of them report a hybrid approach with a limited counter incision under thoracoscopic vision without rib spreading to decrease surgical trauma. Berry *et al.* reported a case series of 105 patients with 12 patients undergoing hybrid VATS treatment with no patient needing conversion to thoracotomy. The VATS-patients had a similar postoperative outcome compared to the thoracotomy-patients and a complete resection was achieved in all patients (25). Also, surgical management of pancoast tumours via minimally invasive surgery has confirmed to be a valid alternative to conventional thoracotomy (26).

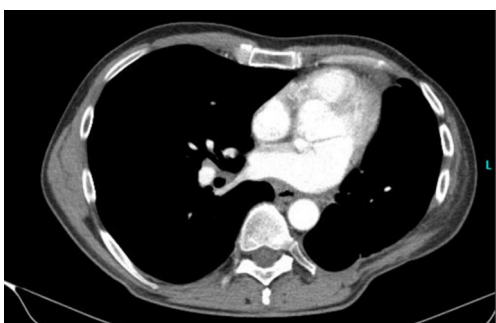In the authors institution, the uniportal VATS-approach is used in selected patient with chest wall infiltration, as described earlier (27,28). Exemplary, we present the case of a 59-year old male patient with a squamous lung cancer of the left lower lobe infiltrating the chest wall (*Figure 2*). A uniportal VATS left lower lobectomy was performed after extensive adhesiolysis, together with the partial resection of the 7<sup>th</sup>, 8<sup>th</sup> and 9<sup>th</sup> ribs via a latissimus muscle-sparing small counter incision (*Figure 3*).

The chest wall reconstruction was performed with a vicryl mesh (*Figure 4*). The postoperative course was uneventful, except for a pleural fistula due to the known emphysema and extensive adhesiolysis. The patient showed no limitations in his mobility or pain on the last follow up 8 months postoperatively (*Figure 5*).

In case of chest-wall-invasion and high operative trauma compared to early stage NSCLC surgery, it can be assumed that less invasive approaches are less painful and therefore short-term outcomes are better. However, because of the



**Figure 4** Intraoperative image showing chest wall reconstruction with vicryl mesh.



**Figure 5** CT-scan 8 months postoperative.

rarity of the clinical presentation there are no larger trials comparing open to minimally invasive surgery and therefore real evidence is missing.

#### **T4N0-1-disease**

Tumours larger than 7 cm and/or infiltrating one of the following structures (heart and great vessels, diaphragm, oesophagus, trachea/carina and vertebral body) are considered stage T4 and therefore at least stage IIIA. With careful patient selection and in specialized surgical units, tumour resection can be performed safely with acceptable morbidity and mortality (29).

The need to use a cardiopulmonary bypass for the resection of tumours invading heart or great vessels has to be planned in advanced and it is mandatory for the patient's safety. A couple of case reports described the feasibility of thoracoscopic vascular sleeve resection with intrapericardial control (30,31), but apart from that, to date the VATS approach in these patients does not seem to be an option.

For tumours with direct extension to the spine, Stoker *et al.* presented in 2013 a case series of a novel, multidisciplinary surgical treatment with VATS-lobectomy

and posterior spinal reconstruction showing the feasibility of these patients in four patients treated this way (32).

In central airway surgery, Gonzales-Rivas first described techniques and feasibility for uniportal VATS bronchoplastic and carinal sleeve procedures (31,33). Early studies are in progress in patients undergoing carinal resection and reconstruction under spontaneous ventilation (34).

Minimally invasive surgery of lung cancer infiltrating diaphragm and oesophagus might play a role in the future as VATS techniques for surgery of oesophageal cancer (35) and benign diseases of the diaphragm (36,37) are evolving. To date, in the literature there are no cases reported for diaphragm or oesophagus en-bloc-resections during lung-cancer surgery.

In conclusion, surgery for locally advanced NSCLC is probably the most complex, even using a classical open approach.

Published cases using VATS are showing promising results regarding short term outcomes, especially in chest-wall-surgery, but larger cohorts and trials are needed.

## **Conclusions**

Answering the question about contraindications for VATS in stage IIIA NSCLC is not simple, as it relates to a very heterogeneous group of patients and surgical challenges.

With the progression in the learning curve of the VATS technique as well as the development of dedicated instrumentation it is plausible that a larger number of cases of stage IIIA lung cancer will be treated through VATS in the near future.

The best evidence in this broad topic is that VATS is safe and oncologically equivalent to open surgery after induction therapy. With many patients being treated in multimodal regimes, neoadjuvant therapy plays a crucial role in the treatment of patients with stage IIIA lung cancer. Yang *et al.* showed that, surgical treatment after induction therapy, short term-outcomes are equivalent or even better in VATS than in thoracotomy and that there is no inferiority of VATS in long term-outcomes (17).

In the treatment of patients with locally advanced IIIA lung cancer there is less evidence to be found for superiority of VATS, as technical feasibility has to be proven.

To date, some promising results for minimally invasive surgery in patients with chest wall involvement were published in literature, but larger patients' cohorts are needed.



For other T3/4-tumours, only little evidence for indication and feasibility of VATS is published. Only a few small cases series and reports are to be found about this subject, while minimally invasive resection of central tumours requiring cardiopulmonary bypass has to be carefully considered.

In conclusion, the practice of VATS-surgery in stage IIIA lung cancer has to be considered carefully in relation to the patient's situation and to the surgical experience of the operating surgeons. Up to date, utilization of VATS seems to be feasible with at least equivalent outcomes in comparison to open surgery in selected cases and the range of indications could be further extended in the future.

### Acknowledgments

*Funding:* None.

### Footnote

*Reporting Checklist:* The authors have completed the Narrative Review reporting checklist. Available at <http://dx.doi.org/10.21037/ccts-20-115>

*Provenance and Peer Review:* This article was commissioned by the Guest Editors (Fabrizio Minervini and Marco Scarci) for the series "Controversies in the Management of Stage IIIA Non-Small-Cell Lung Cancer" published in *Current Challenges in Thoracic Surgery*. The article has undergone external peer review.

*Conflicts of Interest:* All authors have completed the ICMJE uniform disclosure form (available at <http://dx.doi.org/10.21037/ccts-20-115>). The series "Controversies in the Management of Stage IIIA Non-Small-Cell Lung Cancer" was commissioned by the editorial office without any funding or sponsorship. The authors have no other conflicts of interest to declare.

*Ethical Statement:* The authors are accountable for all aspects of the work in ensuring that questions related to the accuracy or integrity of any part of the work are appropriately investigated and resolved. Written informed consent was obtained from the patient for publication of this study and any accompanying images.

*Open Access Statement:* This is an Open Access article distributed in accordance with the Creative Commons

Attribution-NonCommercial-NoDerivs 4.0 International License (CC BY-NC-ND 4.0), which permits the non-commercial replication and distribution of the article with the strict proviso that no changes or edits are made and the original work is properly cited (including links to both the formal publication through the relevant DOI and the license). See: <https://creativecommons.org/licenses/by-nc-nd/4.0/>.

### References

1. Goldstraw P, Chansky K, Crowley J, et al. The IASLC Lung Cancer Staging Project: Proposals for Revision of the TNM Stage Groupings in the Forthcoming (Eighth) Edition of the TNM Classification for Lung Cancer. *J Thorac Oncol* 2016;11:39-51.
2. Sanchez-Lorente D, Guzman R, Boada M, et al. Is it appropriate to perform video-assisted thoracoscopic surgery for advanced lung cancer? *Future Oncol* 2018;14:29-31.
3. Robinson LA, Ruckdeschel JC, Wagner H Jr, et al. Treatment of non-small cell lung cancer-stage IIIA: ACCP evidence-based clinical practice guidelines (2nd edition). *Chest* 2007;132:243S-265S.
4. Zhang W, Wei Y, Jiang H, et al. Thoracotomy is better than thoracoscopic lobectomy in the lymph node dissection of lung cancer: a systematic review and meta-analysis. *World J Surg Oncol* 2016;14:290.
5. Boffa DJ, Kosinski AS, Paul S, et al. Lymph node evaluation by open or video-assisted approaches in 11,500 anatomic lung cancer resections. *Ann Thorac Surg* 2012;94:347-53.
6. Licht PB, Jørgensen OD, Ladegaard L, et al. A national study of nodal upstaging after thoracoscopic versus open lobectomy for clinical stage I lung cancer. *Ann Thorac Surg* 2013;96:943-9; discussion 949-50.
7. Asamura H, Chansky K, Crowley J, et al. The International Association for the Study of Lung Cancer Lung Cancer Staging Project: Proposals for the Revision of the N Descriptors in the Forthcoming 8th Edition of the TNM Classification for Lung Cancer. *J Thorac Oncol* 2015;10:1675-84.
8. Bertoglio P, Ricciardi S, Ali G, et al. N2 lung cancer is not all the same: an analysis of different prognostic groups. *Interact Cardiovasc Thorac Surg* 2018;27:720-6.
9. Postmus PE, Kerr KM, Oudkerk M, et al. Early and locally advanced non-small-cell lung cancer (NSCLC): ESMO Clinical Practice Guidelines for diagnosis, treatment and follow-up. *Ann Oncol* 2017;28:iv1-iv21.

10. Zaccagna G, Zaraca C, Di Leonardo G, et al. Video-assisted thoracoscopic surgery lobectomy in lung cancer after neoadjuvant chemotherapy: feasibility and security analysis through video-assisted thoracoscopic surgery national registry data evaluation. *Curr Chall Thorac Surg* 2020;2:15.
11. Petersen RP, Pham D, Toloza EM, et al. Thoracoscopic lobectomy: a safe and effective strategy for patients receiving induction therapy for non-small cell lung cancer. *Ann Thorac Surg* 2006;82:214-8; discussion 219.
12. Yang CF, Meyerhoff RR, Mayne NR, et al. Long-term survival following open versus thoracoscopic lobectomy after preoperative chemotherapy for non-small cell lung cancer. *Eur J Cardiothorac Surg* 2016;49:1615-23.
13. Suh JW, Park SY, Lee CY, et al. Feasibility and surgical outcomes of video-assisted thoracoscopic pulmonary resection in patients with advanced-stage lung cancer after neoadjuvant chemoradiotherapy. *Thorac Cancer* 2019;10:1241-7.
14. Tian Z, Sui X, Yang F, et al. Is video-assisted thoracoscopy a sufficient approach for mediastinal lymph node dissection to treat lung cancer after neoadjuvant therapy? *Thorac Cancer* 2019;10:782-90.
15. Jeon YJ, Choi YS, Lee KJ, et al. Outcomes of pulmonary resection and mediastinal node dissection by video-assisted thoracoscopic surgery following neoadjuvant chemoradiation therapy for stage IIIA N2 non-small cell lung cancer. *Korean J Thorac Cardiovasc Surg* 2018;51:29-34.
16. Kamel MK, Nasar A, Stiles BM, et al. Video-Assisted Thoracoscopic Lobectomy Is the Preferred Approach Following Induction Chemotherapy. *J Laparoendosc Adv Surg Tech A* 2017;27:495-500.
17. Yang CJ, Nwosu A, Mayne NR, et al. A minimally invasive approach to lobectomy after induction therapy does not compromise survival. *Ann Thorac Surg* 2020;109:1503-11.
18. Hirji SA, Osho A, Balderson SS, et al. Thoracoscopic lobectomy after induction therapy-a paradigm shift? *J Vis Surg* 2017;3:189.
19. Ismail M, Nachira D, Swierzy M, et al. Uniportal video-assisted thoracoscopy major lung resections after neoadjuvant chemotherapy. *J Thorac Dis* 2018;10:S3655-S3661.
20. Chaft JE, Hellmann MD, Velez MJ, et al. Initial experience with lung cancer resection after treatment with T-cell checkpoint inhibitors. *Ann Thorac Surg* 2017;104:e217-e218.
21. Bott MJ, Cools-Lartigue J, Tan KS, et al. Safety and feasibility of lung resection after immunotherapy for metastatic or unresectable tumors. *Ann Thorac Surg* 2018;106:178-83.
22. Bott MJ, Yang SC, Park BJ, et al. Initial results of pulmonary resection after neoadjuvant nivolumab in patients with resectable non-small cell lung cancer. *J Thorac Cardiovasc Surg* 2019;158:269-76.
23. Grillo HC. Technical consideration in stage III disease: pleural and chest wall involvement. In: Delarue NC, Eschappasse H. editors. *International Trends in General Thoracic Surgery*. New York, NY: Saunders, 1985:134-8.
24. Widmann MD, Caccavale RJ, Bocage JP, et al. Video-assisted thoracic surgery resection of chest wall en bloc for lung carcinoma. *Ann Thorac Surg* 2000;70:2138-40.
25. Berry MF, Onaitis MW, Tong BC, et al. Feasibility of hybrid thoracoscopic lobectomy and en-bloc chest wall resection. *Eur J Cardiothorac Surg* 2012;41:888-92.
26. Nun AB, Simansky D, Rokah M, et al. Hybrid video-assisted and limited open (VALO) resection of superior sulcus tumors. *Surg Today* 2016;46:686-90.
27. Gonzalez-Rivas D, Fernandez R, Fieira E, et al. Single-incision thoracoscopic right upper lobectomy with chest wall resection by posterior approach. *Innovations (Phila)* 2013;8:70-2.
28. Giaccone A, Solli P, Pardolesi A, et al. Video-assisted thoracoscopic surgery en bloc chest wall resection. *J Vis Surg* 2017;3:73.
29. Reardon ES, Schrupp DS. Extended resections of non-small cell lung cancers invading the aorta, pulmonary artery, left atrium, or esophagus: can they be justified? *Thorac Surg Clin* 2014;24:457-64.
30. Abu Akar F, Yang C, Lin L, et al. Intra-pericardial double sleeve uniportal video-assisted thoracoscopic surgery left upper lobectomy. *J Vis Surg* 2017;3:51.
31. Gonzalez-Rivas D, Yang Y, Stupnik T, et al. Uniportal video-assisted thoracoscopic bronchovascular, tracheal and carinal sleeve resections†. *Eur J Cardiothorac Surg* 2016;49 Suppl 1:i6-i16.
32. Stoker GE, Buchowski JM, Kelly MP, et al. Video-assisted thoracoscopic surgery with posterior spinal reconstruction for the resection of upper lobe lung tumors involving the spine. *Spine J* 2013;13:68-76.
33. Gonzalez-Rivas D, Yang Y, Sekhniadze D, et al. Uniportal video-assisted thoracoscopic bronchoplastic and carinal sleeve procedures. *J Thorac Dis* 2016;8:S210-S222.
34. Jiang L, Liu J, Gonzalez-Rivas D, et al. Thoracoscopic surgery for tracheal and carinal resection and

- reconstruction under spontaneous ventilation. *J Thorac Cardiovasc Surg* 2018;155:2746-54.
35. Dmitrii S, Pavel K. Uniportal Video-Assisted Thoracic Surgery Esophagectomy. *Thorac Surg Clin* 2017;27:407-15.
36. Kocher GJ, Zehnder A, Schmid RA. Completely Thoracoscopic Diaphragmatic Plication. *World J Surg* 2017;41:1019-22.
37. Viti A, Bertoglio P, Roviglione G, et al. Endometriosis involving the diaphragm: a patient-tailored minimally invasive surgical treatment. *World J Surg* 2020;44:1099-104.

doi: 10.21037/ccts-20-115

**Cite this article as:** Schnorr P, Zalepugas D, Patrini D, Schmidt J, Bedetti B. Stage IIIA non-small cell lung cancer: a contraindication for video-assisted thoracic surgery lobectomy?—a narrative review. *Curr Chall Thorac Surg* 2020.